

Original Article

A Comparative Study of the Early Postoperative Outcome of Three Intramedullary Fixation Modalities in the Treatment of Intertrochanteric Fractures of the Femur in the Elderly

Hongpei Fu[#], Lang Hu[#], Feng Zou[#], Xiaolong Liao[#], Yongling Zheng[#], Peicheng Jin, Junjie Jia, Junchang Xu

Department of Orthopaedics, Xiangyang No.1 People's Hospital, Hubei University of Medicine, Xiangyang, China

[#]Equal contribution

Abstract

Objectives: To compare early outcomes of proximal femoral bionic nail (PFBN), Inter-TAN, proximal femoral nail antirotation (PFNA) for intertrochanteric fractures in elderly patients. **Methods:** Eighty-two elderly patients with intertrochanteric femoral fractures treated at Xiangyang No. 1 People's Hospital affiliated with Hubei University of Medicine from December 2021 to 2022 were retrospectively analyzed. They were categorized into three surgical groups: PFBN (22 cases), Inter-TAN (20 cases), and PFNA (40 cases). Preoperative demographics and fracture characteristics were compared, alongside intraoperative and postoperative metrics like operative time and complication rates. **Results:** In the PFBN group, operative time, fluoroscopy use, blood loss, and transfusion were higher, but postoperative weight-bearing, healing, and hospital stay were shorter compared to the Inter-TAN and PFNA groups ($P < 0.05$). Inter-TAN had a significantly shorter postoperative weight-bearing time than PFNA ($P < 0.001$). Other compared factors showed no significant differences between groups ($P > 0.05$), including complication rates and scores at 6-month follow-up. **Conclusions:** PFBN, a novel surgical approach for intertrochanteric fractures in elderly patients, outperforms Inter-TAN and PFNA by accelerating early weight-bearing and hastening fracture recovery.

Keywords: Elderly, Fracture Internal Fixation, Intramedullary Fixation, Intramedullary Nail, Intertrochanteric Fracture

Introduction

Intertrochanteric femoral fractures are a common and serious type of hip fracture, accounting for approximately 50% of hip fractures in the elderly¹. Population aging has become the new global norm, and China has the largest elderly population in the world, leading to a rapid increase in the number of hip fractures among the elderly². Elderly

individuals are often associated with varying degrees of osteoporosis, and following an intertrochanteric femoral fracture, their normal anatomical structure is compromised. This results in the disruption of the proximal femoral line of force and the continuity of the femoral moment. Additionally, elderly patients frequently suffer from cardiovascular, cerebrovascular, or respiratory diseases, and delays in surgery can lead to higher morbidity and mortality rates³. Therefore, restoring normal anatomy through early-stage surgery after a fracture is an effective way to improve patients' quality of life and reduce complications as soon as possible. Closed reduction intramedullary fixation is an effective surgical method for treating intertrochanteric femoral fractures in the elderly. Intramedullary fixation instruments mainly include gamma nails, Inter-Tan, proximal femoral nails and proximal femoral nail antirotation (PFNA).

Significant differences in early postoperative functional exercise, weight-bearing, and rehabilitation outcomes have been found in patients undergoing different internal

The authors have no conflict of interest.

Corresponding author: Junchang Xu, Department of Orthopaedics, Xiangyang No.1 People's Hospital, Hubei University of Medicine, No. 15 Jiefang Road, Fancheng District, Xiangyang, 441000, Hubei Province, China

E-mail: xjcwgh@163.com

Edited by: G. Lyrītis

Accepted 4 April 2024



fixation procedures. Complications such as hip inversion, head and neck screw cut-outs, and internal fixation breaks have been increasingly reported^{4,5}. Proximal femoral bionic nail (PFBN) was designed and invented for the treatment of this type of fracture⁶⁻⁹. According to the physiological and anatomical characteristics of the proximal femur, the PFBN intramedullary nail remodels the mechanical fulcrum with a triangular stabilizing structure, maintains the relative stability of the fracture site and the internal fixation device, and reconfigures the intertrochanteric fracture with a bionic internal fixation support. This optimizes the force transmission of the proximal femur, which is theoretically more conducive to the healing of intertrochanteric femur fractures in the elderly¹⁰.

For this reason, this study retrospectively analyzed the data of 82 elderly patients with intertrochanteric fractures of the femur treated with PFBN, PFNA, and Inter-TAN intramedullary nailing at Xiangyang No. 1 People's Hospital affiliated with Hubei University of Medicine from December 2021 to December 2022 to compare the early efficacy of these three procedures.

Materials and Methods

Inclusion and exclusion criteria

Inclusion criteria: (i) Patients with a history of trauma and imaging-confirmed intertrochanteric fracture; (ii) Age >60 years; (iii) Patients with closed fresh fractures (<three weeks between injury and surgery); (iv) Patients who are systemically able to tolerate surgery and have signed an informed consent form.

Exclusion criteria: (i) Patients with pathological fractures or metastatic disease; (ii) Patients with a history of ipsilateral lower extremity surgery or dysfunction; (iii) Patients with simultaneous or separate extramedullary fixation; (iv) Patients with an American Society of Anesthesiologists (ASA) grade V; (v) Patients with cognitive impairment or psychiatric disorders.

Efficacy Evaluation Indexes and Criteria

This study retrospectively analyzed the early postoperative clinical outcomes of 82 elderly patients with intertrochanteric fractures of the femur treated with PFBN, Inter-TAN, and PFNA intramedullary nailing between December 2021 and December 2022 at Xiangyang No. 1 People's Hospital affiliated with Hubei University of Medicine. The results of the study will help guide clinicians in choosing the most appropriate internal fixation modality to improve the success rate of surgery, reduce complications, and accelerate patient recovery.

In the study, the researchers collected baseline data from the patients, including age, sex, fracture type, concomitant diseases, duration of surgery, intraoperative conditions, and postoperative recovery. By analyzing this data, the researchers were able to compare the clinical outcomes of different internal fixation modalities in the early postoperative

period, including pain relief, functional recovery, fracture healing time, and complication rates. Additionally, the study also considered patients' quality of life, assessing their postoperative satisfaction and ability to live through questionnaires and follow-up visits.

Patients' general information such as sex, age, bone mineral density (BMD), side of injury, fracture AO/OTA staging, surgical method, and follow-up time were recorded. The basic perioperative conditions of the patients were documented, including the time from injury to surgery, intraoperative bleeding, intraoperative fluid infusion, number of intraoperative fluoroscopies, and operative duration (from the beginning of skin incision until all wounds were closed). We rely on the hospital's medical record system to establish and maintain patient records and develop a postoperative follow-up program according to uniform standards.

The surgical team was grouped to establish contact with the patients. Through telephone follow-ups, each patient was regularly notified to come to the hospital for a review at an agreed time. In case of an emergency, the patient was instructed to contact the responsible physician and come to the hospital for a check-up. Review imaging data were recorded to observe fracture healing and the occurrence of fracture treatment complications (including internal fixation cut-out, nail fracture/peri-internal fixation fracture, bone discontinuity, and ischemic necrosis of the femoral head). The hip fracture function recovery scale (FRS) and the hip Harris score standard were used to assess the hip function of the affected limb at the last follow-up. Dual-energy X-ray absorptiometry (DXA) measurements are currently the common diagnostic index for osteoporosis.

In this study, all surgical patients underwent preoperative DXA bone densitometry. The diagnostic criteria for osteoporosis were as follows: T value ≥ -1.0 : normal bone mass; $-2.5 < T \text{ value} < -1.0$: reduced bone mass; T value ≤ -2.5 : osteoporosis; T value ≤ -2.5 combined with fragility fracture: severe osteoporosis. Referring to Baer et al.'s¹¹ grading of postoperative hip mobility, ambulation, and pain assessment in elderly hip fracture patients, the surgical team provided a uniform assessment and instruction for each postoperative patient.

The criteria used in this study to assess the initiation of postoperative weight-bearing were: (i) the affected limb could be flexed at 60-80° at the hip; (ii) the patient could walk with the help of crutches or walkers; (iii) mild pain during walking, which was relieved at rest.

When postoperative patients met all three criteria simultaneously, they were allowed to carry out weight-bearing activities on the ground, and the weight-bearing time was recorded.

The criteria for discharge were: (i) the patient's vital signs were stable and the general condition was good; (ii) there was no significant abnormality in the infection index review; (iii) the postoperative X-ray showed good alignment of the fracture end and satisfactory position of the internal fixation; (iv) the criteria for starting weight-bearing after surgery were met.

Patients were discharged after meeting all four discharge criteria.

The criteria for fracture healing were: (i) no local pressure pain and no longitudinal percussion pain; (ii) no abnormal local activity; (iii) X-ray plain film showed continuous bone callus at the fracture site and a blurred fracture line.

When the postoperative patient met the first two criteria, it was considered initial fracture healing. When the postoperative patient was reviewed for three consecutive times, and the X-ray showed that the bone callus at the fracture site passed through the fracture line, did not increase significantly, and the fracture line was close to disappearing or had disappeared, the fracture was considered healed. The time of fracture healing was taken as the time of the last review.

Surgical Method

In this study, a single surgical team operated on all patients, who were prepared for surgery with adjustments made for any co-existing medical conditions. Anesthesia was tailored to the patient's condition, and the surgical setup included positioning the patient supine with a pillow under the affected hip and a traction bed prepared. Manual repositioning of the affected limb was performed, with closed repositioning standards checked under C-arm X-ray. If necessary, bone pins and periosteal strippers were used to assist through a small incision. Once repositioning was satisfactory, the limb was fixed in place.

For the PFBN group, after confirming the PFBN nail's placement with a C-arm X-ray, the guide pin was removed, and the PFBN components were sequentially placed. The appropriate locking nail length was secured, and the nail's tail cap was fixed.

In the Inter-TAN group, following the confirmation of the Inter-TAN's location in the medullary cavity, the guide pin was driven into the femoral neck, and an anti-rotation blade was hammered into place. After checking the guide pin's position with fluoroscopy, the femoral neck main nail was inserted, and the anti-rotation blade was replaced with a pressurized anti-rotation locking screw. The locking nail was then secured with a distal locking nail sight.

For the PFNA group, once the PFNA's location was confirmed, the guide pin was driven into the femoral head and neck, and the locking nail and cephalomedullary nail's caudal cap were fixed in place.

After satisfactory repositioning and intramedullary nail system placement, the wound was flushed with saline, closed layer by layer, and checked for active bleeding before applying the final dressing.

Perioperative Management

Upon admission to the hospital, the medical team initiated a comprehensive monitoring and treatment program to ensure the best possible outcome for the patient. Initially, the medical staff conducted a meticulous assessment of

the patient's condition, including pain level, vital signs, and blood test results, to adjust the treatment plan promptly. Symptomatic supportive therapy, which includes pain relief, anti-inflammatory medication, nutritional support, and electrolyte supplementation, was provided to alleviate symptoms and improve comfort.

Special emphasis was placed on preventing deep vein thrombosis (DVT) in the lower extremities. Ankle pumping exercises were encouraged to promote venous blood return through repeated ankle flexion and extension, simulating the action of a muscle pump. Additionally, the patient received low molecular weight heparin calcium injections, an effective anticoagulant that reduces blood clotting and prevents clot formation. This preventive measure was initiated preoperatively and continued postoperatively to ensure the patient's safety throughout the treatment process.

Prior to surgery, patients followed strict fasting guidelines, abstaining from food and drink for at least 6 hours to reduce the risk of vomiting during anesthesia and postoperatively, as well as to avoid complications such as aspiration pneumonia. Thirty minutes before surgery, patients received antibiotic prophylaxis to reduce the risk of postoperative infections, particularly during invasive procedures. None of the patients underwent catheterization during surgery, which helps minimize the risk of postoperative urinary tract infections. Additionally, no drains were left in place postoperatively, reducing patient discomfort and shortening hospital stays. No blood transfusions were administered during the procedures.

After anesthesia recovery, patients were instructed to continue ankle pumping exercises and received limb pneumatic compression therapy on the ward to promote blood circulation in the lower limb and prevent postoperative complications such as swelling and thrombosis. The medical team closely monitored changes in the patient's hip mobility, encouraging early movement to assess joint function. Once hip mobility exceeded 50°, a postoperative bedside radiograph review was conducted to ensure stable and correct alignment of the fracture site, essential for assessing surgical outcomes and guiding subsequent treatment.

On the first postoperative day, patients began prophylactic treatment with low molecular weight heparin calcium injections and performed functional exercises in bed under the guidance of the medical team to build muscle strength and improve joint mobility while preventing lower extremity deep vein thrombosis. Upon discharge, patients switched to oral rivaroxaban tablets for continued thrombosis prophylaxis until the 30th postoperative day.

The medical team also provided psychological support and education throughout the treatment process, informing patients about potential postoperative situations and how to manage them. Patients and families received education on providing appropriate care at home, including wound care, medication management, and activity and dietary instructions, to ensure successful recovery after discharge.

Table 1. Patient characteristics and treatment aspects per implant type.

Characteristic	PFBN (N=22)	Inter-TAN (N=20)	PFNA (N=40)	P value
Patient characteristic				
Sex (male, female)	(10, 12)	(7, 13)	(13, 27)	0.590
Mean age (years, SD)	(76.27, 4.47)	(80.55, 7.05)	(79.15, 7.82)	0.121
BMD (g/cm ³ , SD)	(-3.13, 0.40)	(-3.40, 0.38)	(-3.31, 0.55)	0.163
Fracture side(left, right)	(12, 10)	(11, 9)	(19, 21)	0.805
Fracture Type (A1.3, A2.2, A3.1, A3.3)	(6, 7, 6, 3)	(13, 3, 2, 2)	(14, 7, 7, 12)	0.117*
Combined medical diseases (A, B, C, D)	(13, 15, 6, 15)	(8, 11, 1, 13)	(22, 21, 5, 22)	0.819*
Injury to surgery time [d, M (P25, P75)]	3.5 (3, 5)	4 (3, 5.75)	4 (3, 6)	0.412
Causes of injury (fall injuries, traffic injuries, other injuries)	(13, 4, 5)	(15, 2, 4)	(32, 4, 4)	0.445*
Treatment aspects				
Time to surgery(min, SD)	(70.45, 6.89)	(58.7, 5.89) ^a	(60, 6.58) ^b	<0.001
Intraoperative fluoroscopy number [Views, M (P25, P75)]	6 (6, 7)	5.5 (5, 6) ^a	5.5 (5, 6) ^b	<0.001
Intraoperative bleeding (mL, SD)	(161.82, 35)	(128.5, 21.83) ^a	(131.5, 23.49) ^b	<0.001
Intraoperative fluid volume [mL, M (P25, P75)]	1500(1300, 1800)	1000(925, 1000) ^a	1200(1000, 1200) ^b	<0.001
Weight bearing time (d, SD)	(6.05, 1.13)	(14.5, 1.57) ^a	(21.18, 3.54) ^{b,c}	<0.001
Fracture healing time (w, SD)	(14.45, 1.41)	(15.65, 1.18) ^a	(16.35, 1.76) ^b	<0.001
Complication rate (% , cases)	0 (0/22)	5 (1/20)	5 (2/40)	0.612*
FRS score (6 months post-operative) (points, SD)	(82.14, 2.95)	(81.2, 3.89)	(82.18, 2.59)	0.473
Hip Harris score excellent rate (% , cases)	86.4 (3/22)	85 (3/20)	85 (6/40)	1.000*
Hospitalization time (d, SD)	(8.14, 1.21)	(14.8, 3.17) ^a	(13.2, 3.24) ^b	<0.001

*SD standard deviation, M median, g/cm grams per cubic centimeter, ml millilitre, d days, h hours, w weeks, % percentages, A cardiovascular disease, B primary hypertension, C diabetes mellitus, D other internal diseases, ^aP<0.05 for the Inter-TAN group compared with the PFBN group, ^bP<0.05 for the PFNA group compared with the PFBN group, ^cP<0.05 for the PFNA group compared with the Inter-TAN group. Italics indicate statistical significance (P<0.05), *Fisher's exact test.*

Statistical analysis

The statistical software IBM SPSS 27.0 (SPSS IBM, New York, USA) was used for analysis. Count data including sex, fracture side, fracture AO/OTA typing, combined disease, cause of injury, and excellent rate (hip Harris score) were compared using the Chi-square test.

For measurement data, normal distribution was initially determined using the Shapiro-Wilk test. Age, BMD, operation time, intraoperative bleeding, postoperative weight-bearing time, FRS score (6 months postoperative), fracture healing time, and hospitalization time were found to be normally distributed and expressed as mean \pm standard deviation ($\bar{x} \pm s$). Levene's test was used to determine the mean square difference, and pairwise comparisons were conducted using LSD-t test. One-way ANOVA was used for triadic comparison.

Non-normally distributed data, including the time from injury to surgery, number of intraoperative fluoroscopies, intraoperative fluid infusion volume, fracture healing time, and postoperative FRS score, were expressed as median M (P25, P75). Nonparametric tests were applied, and if the differences were statistically significant, the Kruskal-Wallis test was used for two-way comparisons between groups.

A significance level of $P < 0.05$ was considered statistically significant.

Results

All patients underwent a 6-month postoperative follow-up. The differences in preoperative general data, such as sex, age, BMD, fracture side, fracture AO/OTA typing, combined medical diseases, time from injury to surgery, and cause of injury, were not statistically significant among the three groups ($P > 0.05$, Table 1), indicating comparability.

The operating duration, intraoperative bleeding, intraoperative infusion volume, and the number of intraoperative fluoroscopies were significantly higher in patients in the PFBN group than in the Inter-TAN and PFNA groups, with statistically significant differences ($P < 0.05$, Table 1). Conversely, the postoperative weight-bearing time, fracture healing time, and hospital stay were significantly shorter in patients in the PFBN group compared to those in the Inter-TAN and PFNA groups, with statistically significant differences ($P < 0.05$, Table 1).

The postoperative weight-bearing time in the Inter-TAN group was shorter than that in the PFNA group, with

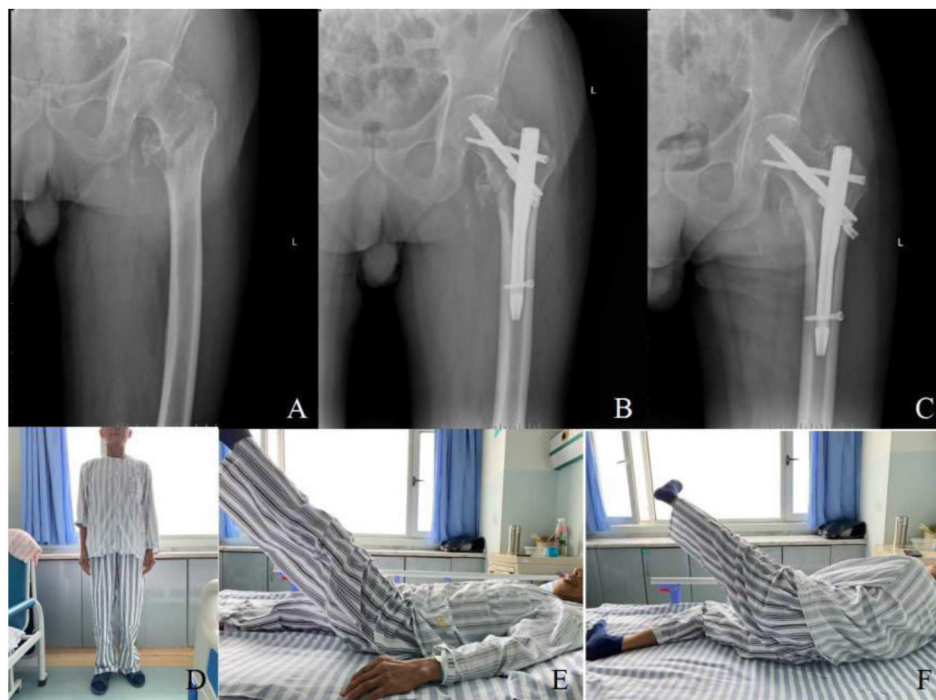


Figure 1. Pre- and postoperative X-rays and postoperative functional photographs of PFBN: A. Preoperative left femur in orthostatic position. B. Left femur in orthostatic position reviewed at 1 day postoperatively. C. Right femur in orthostatic position at 3 months postoperatively. D to F. Patients' primary functional position at 3 months postoperatively.

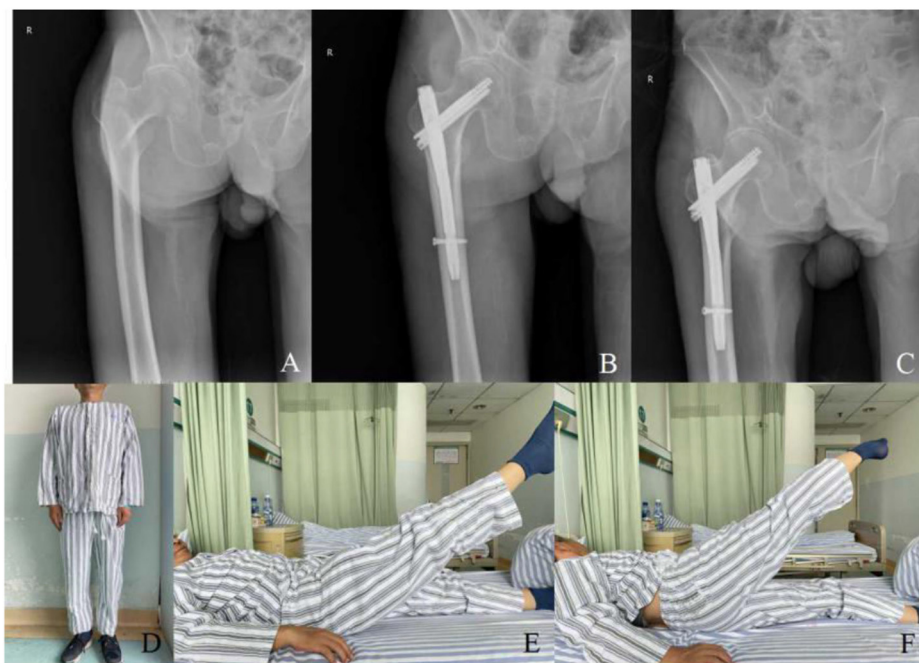


Figure 2. Pre- and postoperative X-ray and postoperative functional photographs of Inter-TAN: A. Preoperative right femur in orthostatic position. B. Right femur in orthostatic position reviewed at 1 day postoperatively. C. Right femur in orthostatic position at 6 months postoperatively. D to F. Patients' primary functional position at 6 months postoperatively.

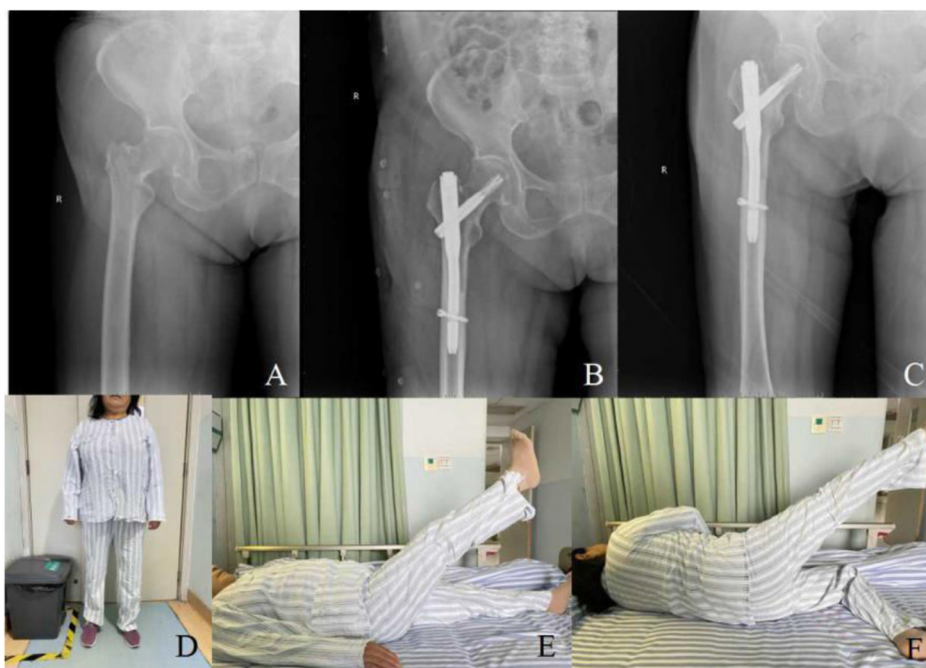


Figure 3. Pre- and postoperative X-ray and postoperative functional photographs of PFNA: A. Preoperative right femur in orthostatic position. B. Right femur in orthostatic position reviewed at 4 days postoperatively. C. Right femur in orthostatic position at 5 months postoperatively. D to F. Patients' primary functional position at 5 months postoperatively.

a statistically significant difference ($P < 0.001$, Table 1). However, the operative duration, intraoperative bleeding, intraoperative fluid infusion volume, number of intraoperative fluoroscopies, fracture healing time, and hospital stay in the Inter-TAN group did not significantly differ from those in the PFNA group ($P > 0.05$, Table 1).

During the follow-up period, there were no postoperative complications in the PFBN group, one case of DVT in the Inter-TAN group, and two cases of DVT in the PFNA group. None of the three groups of internal fixation devices experienced complications such as fracture or screw dislodgement.

There were no statistically significant differences in the incidence of surgical complications, FRS scores, and hip Harris scores among the three groups ($P > 0.05$, Table 1). Typical cases are illustrated in Figures 1 to 3, while the PFBN model is depicted in Figure 4.

Discussion

Intertrochanteric fractures, which commonly affect the elderly, extend beyond the hip capsule line and are typically managed with intramedullary or extramedullary fixation. Extramedullary fixation is suitable for stable fractures but less effective for unstable ones¹² intramedullary fixation, preferred for its shorter force arm, higher fixation strength,

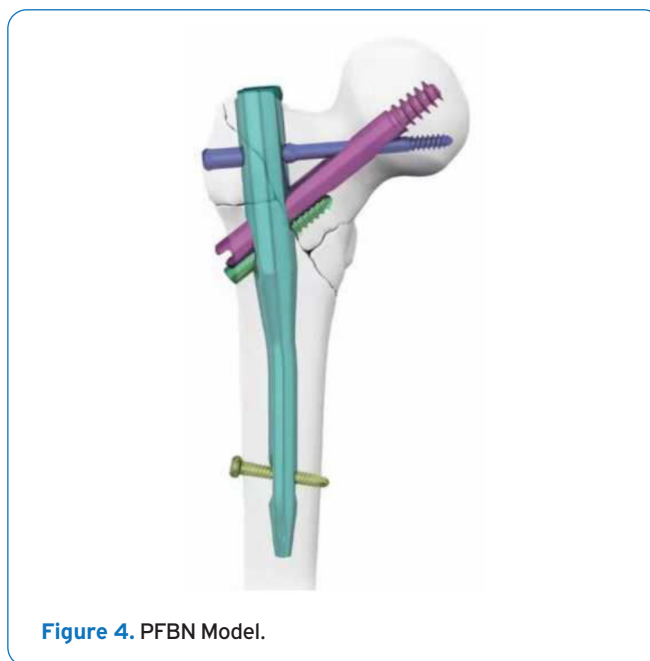


Figure 4. PFBN Model.

and reduced surgical trauma, demonstrates clinical efficacy across all AO/OTA subtypes¹³. Studies^{14,15} suggest that early weightbearing in elderly patients does not increase the risk of implant failure or worsen outcomes. Instead, it reduces hospital stays, postoperative pain, and improves ambulation, enabling patients to achieve full weightbearing more quickly.

A comparative analysis reveals that the Inter-TAN group exhibited superior early postoperative activity and faster weight-bearing times compared to the PFNA group, with no notable difference in hospitalization time. The Inter-TAN's double-screw interlocking structure offers enhanced horizontal tension but may potentially lead to increased bone loss. Postoperative hip mobility and early rehabilitation exercises are encouraged, with the PFBN group demonstrating superior performance, which aligns with its design for early rehabilitation and aims to reduce postoperative bed rest and hospital stay.

The PFBN group exhibited significantly longer operative times and required more intraoperative fluoroscopies compared to the Inter-TAN and PFNA groups, indicating the necessity for precise anatomical repositioning and careful screw placement to minimize the need for fluoroscopic confirmations and adjustments. Surgeons universally prioritize minimizing bleeding and infusion during surgery, with particular attention to hidden blood loss (HBL), especially in elderly patients with varying degrees of osteoporosis¹⁶. Both systemic and topical application of tranexamic acid have proven effective in reducing HBL and the need for transfusions without increasing thromboembolic risks^{17,18}. The higher intraoperative blood loss and fluid infusion in the PFBN group can be attributed to its surgical approach, which involves placing lateral support screws, thus prolonging operative time and necessitating larger incisions. Tranexamic acid is recommended for elderly patients to mitigate venous bleeding and local bone surface bleeding, thereby shortening healing time. Importantly, there were no significant differences in complication rates, 6-month postoperative FRS scores, or excellent hip Harris scores among the three groups, suggesting no clear advantage in long-term functional recovery.

Structural defects such as those affecting the lateral wall can significantly impact the mechanical stability of intertrochanteric fractures¹⁹. PFNA, commonly utilized for these fractures, incorporates a helical blade that enhances local bone density but may result in penetration and necessitate secondary revision surgery if the lateral wall is compromised²⁰. Inter-TAN offers improved anti-rotation and compression resistance^{21,22} but may contribute to increased intraoperative bleeding and operative time, potentially leading to higher complication rates^{23,24}.

The primary objective of any intramedullary fixation is to restore the anatomy of the proximal femur and align the lower extremity. PFBN's double triangular support structure provides stable support²⁵, and finite element analysis²⁶ demonstrates its ability to enhance lateral stability and tension resistance, thereby reducing stress concentration and bone junction damage, consequently lowering the

risk of complications. However, ensuring proper fracture repositioning before nail placement is essential, and meticulous determination of the pressure screw's position and nail length is imperative.

This study has limitations, including clinicians' unfamiliarity with PFBN instruments, a short follow-up period, a small sample size, and inherent selective bias in the retrospective study design. Additionally, the absence of intraoperative transfusions across groups may obscure differences in occult blood loss resulting from differences in operation durations and blood loss amounts.

Conclusions

In conclusion, compared to InterTan and PFNA intramedullary fixation, PFBN internal fixation for intertrochanteric femur fractures in the elderly demonstrates superior early efficacy, shorter time to partial weight-bearing postoperatively, and accelerated fracture healing. Moreover, PFBN, as a novel fixation technique for intertrochanteric fractures, presents a promising new option for their treatment.

Ethics approval

This study was approved by the ethics committee of Xiangyang No.1 People's Hospital (approval number: XYYYE20220023).

Funding

This study was supported by the Chinese Medicine Research Project of Hubei Provincial Administration of Traditional Chinese Medicine (contract grant number: ZY2023FO88).

Authors' contributions

HF and LH conceived and designed the study and drafted the manuscript. FZ, XL, and YZ collected, analyzed, and interpreted the experimental data. PJ, JJ, and JX revised the manuscript for important intellectual content. All authors read and approved the final manuscript.

References

1. TJ, Kwek EBK. Are Intertrochanteric Fractures Evolving? Trends in the Elderly Population over a 10-Year Period. *Clin Orthop Surg* 2022;14(1):13-20.
2. Zhang Z, Qiu Y, Zhang Y, Zhu Y, Sun F, Liu J, Zhang T, Wen L. Global Trends in Intertrochanteric Hip Fracture Research From 2001 to 2020: A Bibliometric and Visualized Study. *Front Surg* 2021;8:756614.
3. Fischer H, Maleitzke T, Eder C, Ahmad S, Stöckle U, Braun KF. Management of proximal femur fractures in the elderly: current concepts and treatment options. *Eur J Med Res* 2021;26(1):86.
4. Mu JX, Xiang SY, Ma QY, Gu HL. Selection of internal fixation method for femoral intertrochanteric fractures using a finite element method. *World J Clin Cases* 2021;9(22):6343-6356.
5. Su Z, Yang M, Luo G, Liang L, Hao Y. Treatment of Elderly Femoral Intertrochanteric Fracture by InterTan

- Intramedullary Nail and PFNA. *Evid Based Complement Alternat Med* 2022;2022:5020960.
6. Zhang DY. The past and future of internal fixation for femoral intertrochanteric fractures: a perspective from "lever fulcrum reconstruction" theory. *Chin J Orthop Trauma* 2020; 22(10): 841-845.
 7. Zhang DY. Proximal femoral bionic force arm reconstruction supporting anti-rotation intramedullary nail system. China National Intellectual Property Administration. <https://pss-system.cnonline.cnipa.gov.cn/conventionalSearchEn>. Application No.CN201821045324.7. Accessed 13 October 2023.
 8. Zhang DY, Yu K, Yang J, et al. Lever-pivot balance: a neodoxy on treatment for intertrochanteric femoral fractures. *Chin J Trauma* 2020;36(7):647-651.
 9. Ding K, Zhu Y, Li Y, Wang H, Cheng X, Yang W, Zhang Y, Chen W, Zhang Q. Triangular support intramedullary nail: A new internal fixation innovation for treating intertrochanteric fracture and its finite element analysis. *Injury* 2022;53(6):1796-1804.
 10. Zhang YZ, Wang HC, Chen W, et al. Triangular support fixation: an innovation of intertrochanteric fracture surgery: evidence from biomechanical research. *Chin J Trauma Orthopedics* 2021;23(6):461-466.
 11. Baer M, Neuhaus V, Pape HC, Ciritsis B. Influence of mobilization and weight bearing on in-hospital outcome in geriatric patients with hip fractures. *SICOT J* 2019;5:4.
 12. Memon K, Siddiqui AM, Khan ZA, Zahoor A. Dynamic Hip Screw Fixation Vs. Proximal Femur Nail For Unstable Per-Trochanteric Fractures: A Comparative Analysis Of Outcomes And Complications. *J Ayub Med Coll Abbottabad* 2021;33(1):34-38.
 13. Adeel K, Nadeem RD, Akhtar M, Sah RK, Mohy-Ud-Din I. Comparison of proximal femoral nail (PFN) and dynamic hip screw (DHS) for the treatment of AO type A2 and A3 pertrochanteric fractures of femur. *JPMA. J Pak Med Assoc* 2020;70(5):815-819.
 14. Atzmon R, Drexler M, Ohana N, Nyska M, Palmanovich E, Dubin J. The effect of post-operative weight-bearing status on mortality rate following proximal femoral fractures surgery. *Archives of orthopaedic and trauma surgery* 2022;142(6):947-953.
 15. Jia X, Qiang M, Zhang K, Han Q, Wu Y, Chen Y. Influence of Timing of post-operative Weight-Bearing on Implant Failure Rate Among Older Patients With Intertrochanteric Hip Fractures: A Propensity Score Matching Cohort Study. *Front Med (Lausanne)* 2021;20:8:795595.
 16. Cui H, Chen K, Lv S, Yuan C, Wang Y. An analysis of perioperative hidden blood loss in femoral intertrochanteric fractures: bone density is an important influencing factor. *BMC Musculoskelet Disord* 2021;22(1):6.
 17. Zhang S, Xiao C, Yu W, Long N, He F, Cai P, Luo K, Jiang Y. Tranexamic acid safely reduces hidden blood loss in patients undergoing intertrochanteric fracture surgery: a randomized controlled trial. *Eur J Trauma Emerg Surg* 2022;48(2):731-741.
 18. Lin JA, Cui HD, Hong Y, Lyu SJ. Application of tranexamic acid in the treatment of intertrochanteric fracture of femur. *Zhongguo Gu Shang* 2021;34(7):601-4.
 19. Shi Z, Qiang M, Jia X, Zhang K, Chen Y. Association of the lateral wall integrity with clinical outcomes in older patients with intertrochanteric hip fractures treated with the proximal femoral nail anti-rotation-Asia. *Int Orthop* 2021;45(12):3233-3242.
 20. Mu W, Zhou J. PFNA-II Internal Fixation Helps Hip Joint Recovery and Improves Quality of Life of Patients with Lateral-Wall Dangerous Type of Intertrochanteric Fracture. *Biomed Res Int* 2021;2021:5911868.
 21. Yoon JY, Park S, Kim T, Im GI. Cut-out risk factor analysis after intramedullary nailing for the treatment of extracapsular fractures of the proximal femur: a retrospective study. *BMC Musculoskelet Disord* 2022;23(1):107.
 22. Lee YK, Kim JT, Park CH, Song JU, Kim TY, Koo KH. Analysis of risk factor for nail breakage in patients with mechanical failures after proximal femoral nail antirotation in intertrochanteric fractures. *Medicine (Baltimore)* 2022;101(25):e29436.
 23. Chang SM, Hou ZY, Hu SJ, Du SC. Intertrochanteric Femur Fracture Treatment in Asia: What We Know and What the World Can Learn. *Orthop Clin North Am* 2020;51(2):189-205.
 24. Nie SB, Zhang W, Zhang LC, et al. Progress in the study of risk factors for internal fixation failure after intertrochanteric fracture. *Chin J Trauma Orthopedics* 2021; 23(3): 233-238.
 25. Wang H, Yang W, Ding K, Zhu Y, Zhang Y, Ren C, Zhao K, Zhang Q, Chen W, Zhang Y. Biomechanical study on the stability and strain conduction of intertrochanteric fracture fixed with proximal femoral nail antirotation versus triangular supporting intramedullary nail. *Int Orthop* 2022;46(2):341-350.
 26. Wang Y, Chen W, Zhang L, Xiong C, Zhang X, Yu K, Ju J, Chen X, Zhang D, Zhang Y. Finite Element Analysis of Proximal Femur Bionic Nail (PFBN) Compared with Proximal Femoral Nail Antirotation and InterTan in Treatment of Intertrochanteric Fractures. *Orthop Surg* 2022;14(9):2245-2255.