

## Clinical Quiz

## Pregnancy associated osteoporotic vertebral fractures: an underdiagnosed condition of back pain

Constantinos Chaniotakis<sup>1</sup>, Christos Koutserimpas<sup>2</sup>, Konstantinos Raptis<sup>2</sup>, Evaggelos Zafeiris<sup>3</sup>, Kalliopi Alpantaki<sup>1</sup>, Grigoris Effraimidis<sup>4</sup>

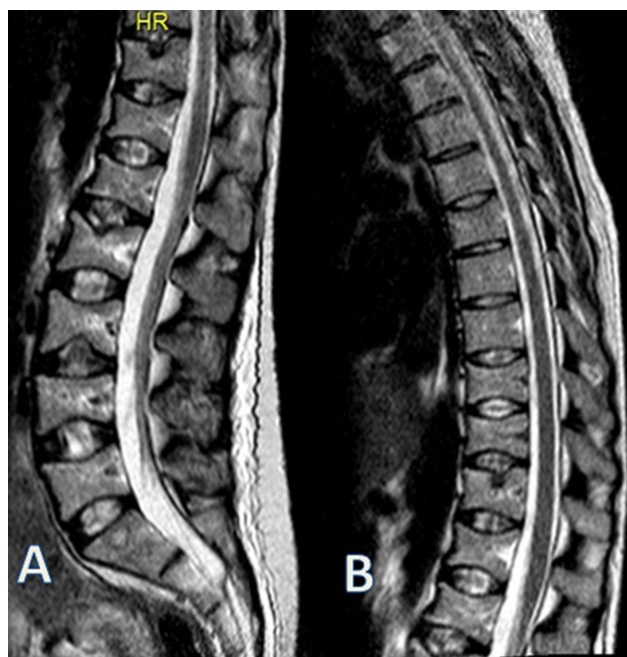
<sup>1</sup>Department of Orthopaedics and Trauma Surgery, Venizeleio General Hospital of Heraklion, Crete, Greece;

<sup>2</sup>Department of Orthopaedics and Traumatology, "251" Hellenic Air Force General Hospital of Athens, Greece;

<sup>3</sup>2<sup>nd</sup> Orthopaedic Department, "Konstantopouleio" General Hospital of Athens, Greece;

<sup>4</sup>Department of Medical Endocrinology, Rigshospitalet, Copenhagen University Hospital, Copenhagen, Denmark

**Keywords:** Back Pain Pregnancy, Pregnancy-Associated Osteoporosis, Pregnancy Related Osteoporosis, Vertebral Fracture



**Figure 1.** Multiple vertebral compression fractures (T11, T12, L1, L2, L3).

### Case

A 30 year-old female, during the second month after delivering her first child, presented to the out-patient orthopaedic clinic, complaining of severe low back pain without any history of traumatic event. The patient's remaining medical history was unremarkable. Upon physical examination her height had decreased about 4 cm during pregnancy and experienced persistent thoracolumbar pain, while there was no neurological deficit. Plain radiographs and magnetic resonance imaging (MRI) of thoracolumbar spine detected multiple vertebral compression fractures (T11, T12, L1, L2, L3) (Figure 1).

Biochemical markers of bone turnover revealed a deficiency of 25(OH)-Vitamin D level (9,6 ng/ml) and an increase of bone ALP level (60,1 ng/ml). Other biochemical markers were in normal range. A subsequent dual-energy X-ray absorptiometry (DEXA) scan found decreased areas of bone mineral density (BMD) in the lumbar spine (L1-L4, 0.617 g/cm<sup>2</sup>, Z-score -4.4), femoral neck (0.551 g/cm<sup>2</sup>, Z-score -3.6), and total hip (0.528 g/cm<sup>2</sup>, Z-score -3.9) (Table 1).

According to the clinical symptoms, laboratory examinations and imaging characteristics, the diagnosis of pathologic thoracolumbar fractures secondary to pregnancy associated osteoporosis (PAO) was established. Treatment included cessation of breastfeeding and application of a thoracolumbar orthosis. Additionally, she received daily per os vitamin D and calcium supplementation (800 mg Vitamin D-1200 mg Ca) and anabolic therapy with teriparatide (20 µg/day) for a 24-month duration.

At the latest follow-up, 15 months following treatment initiation, the patient is free of pain and she returned to her previous activities with minor discomfort.

The authors have no conflict of interest.

Corresponding author: Christos Koutserimpas, Department of Orthopaedics and Traumatology, "251" Hellenic Air Force General Hospital of Athens, Greece

E-mail: chrisku91@hotmail.com

Edited by: G. Lyrakis

Accepted 18 November 2020

**Table 1.** Main characteristics of the presented case.

Age	30 year-old
Time at presentation	2 <sup>nd</sup> month of postpartum period
Spinal fracture(s)	T11,T12,L1,L2,L3
Lumbar spine T score / Z score	-4,4/ -4,4
BMD (gr/cm <sup>2</sup> )	0,617
Calcium level (mg/dl)	9,4
Phosphate level (mg/dl)	3,8
PTH (pg/ml)	10,4
25(OH)-Vitamin D (ng/ml)	9,6
Treatment	Vitamin D and calcium supplements Teriparatide
Follow- up	15 months

## Commentary

PAO related fragility fractures impact women's health and well-being during the last trimester of pregnancy (40%) or in the early postpartum period (60%), usually 3 months following child-birth<sup>1</sup>. The vast majority of PAO fractures are localized at the thoracolumbar spine, while cases of PAO related hip fractures have also been reported<sup>1</sup>.

The main clinical signs and symptoms of osteoporotic vertebral compression fractures include the acute onset of severe back pain resulting in limited mobility and progressive loss of height, while thoracolumbar spine is the most common fracture site<sup>1</sup>.

Pregnancy related osteoporotic vertebral compression fractures (OVCFs) occur due to a combination of metabolic and mechanical factors<sup>2,3</sup>. Bone loss has been observed during pregnancy and takes place mainly at the trabecular sites of the skeleton. The mechanical alterations during pregnancy affect the anatomy of the spine resulting in height loss and increasing lumbar lordosis<sup>2</sup>. Contributing risk factors include low body mass index (BMI), reduced physical activity, poor nutrition, inadequate calcium intake, vitamin D insufficiency, smoking, oligomenorrhea, gluten enteropathy, glucocorticoids intake and LMWH administration<sup>2,3</sup>. The present patient had vitamin D deficiency.

Pregnancy is related to decreasing bone mass. During the last trimester of pregnancy, 30 gr of calcium are provided to fetal skeleton from maternal sources in order to meet its requirements (substantial growth and calcification). In the postpartum period, the major cause of maternal calcium loss is breastfeeding. The average loss of calcium is 210 mg per day in breast milk<sup>2,3</sup>. These adaptations may lead to maternal skeletal resorption and temporary decrease in BMD. During these periods, some women may suffer from fragility fractures<sup>2</sup>. The overall deficit is normally restored to baseline values in the period following the lactation<sup>2</sup>. According to other hypotheses, the increase in parathyroid hormone-

related peptide (PTH-rP) secretion by lactation, the decrease in estrogen levels after delivery, the pre-existing osteopenia and heritable factors (mutations in lipoprotein receptor-related protein 5) contribute to the appearance of PAO<sup>1,2</sup>.

Dual-energy x-ray absorptiometry (DEXA) is the modality of choice for measuring bone mineral density (BMD) and identifying osteoporosis or osteopenia<sup>4</sup>. BMD is not measured routinely in premenopausal women and consequently a direct comparison between preconceptional BMD and BMD after childbirth in large series is not available. However, studies have suggested BMD reduction during pregnancy in around 5% of pregnant women<sup>2,4</sup>. In most cases fragility fractures will be confirmed by conventional radiography. Computed Tomography (CT) is contraindicated during pregnancy, while Magnetic Resonance Imaging (MRI) may be safely performed. MRI detects bone marrow edema and has high sensitivity and specificity in the diagnosis of OVCF<sup>3</sup>. The reported case had findings in both plain x-rays and MRI.

PAO is considered a self-limiting disease and spontaneous improvement of BMD in pre-pregnancy levels is typically expected 12-18 months after lactation<sup>1</sup>. Therefore, the management is mainly conservative, including optimal calcium and vitamin D intake and appropriate physical activity and exercise, in non-severe cases<sup>5</sup>. Some authors suggest the cessation of breastfeeding, in order to decrease the deteriorations in maternal skeleton<sup>2,5</sup>. This may reduce the fluctuations in the concentrations of calcium. Contrary to postmenopausal osteoporosis, the pharmacological management of PAO is generally challenging, due to the limited evidence and the absence of clinical guidelines. The pharmacological treatment consists of bisphosphonates, teriparatide, denosumab and strontium ranelate<sup>5</sup>. One year of bisphosphonates administration may lead to 23% increase in spinal BMD over the next 2 years, in cases that treatment was initiated during the first year following the diagnosis<sup>1,5</sup>. Nevertheless, bisphosphonates' main adverse effects, such as their prolonged skeletal retention and the crossing of the placenta restrict their use in severe cases. The potential harm for fetus limits their prescription in women wishing to conceive in the future<sup>5</sup>. However, a literature review of 78 women receiving bisphosphonates did not find evidence to significant harm of the fetus<sup>5</sup>. Teriparatide, the human recombinant parathyroid hormone, may be beneficial for both pain relief and BMD induction, as BMD may be increased by up to 36%<sup>5</sup>. The surgical treatment consists of vertebroplasty and kyphoplasty. The use of these approaches has been mentioned in individual cases, but the overall efficacy remains uncertain<sup>3,5</sup>. The present case was treated with calcium and vitamin D intake, with the addition of Teriparatide due to the presence of multiple fractures, the very low BMD/Z-score and the severe clinical presentation. Breastfeeding was also ceased.

Back pain in women during the last trimester of pregnancy or the postpartum period should always be alarming and OVCF should be considered in the differential diagnosis. Appropriate investigation and management is recommended in order to prevent further complications.

## References

1. Hardcastle SA, Yahva F, Bhalla AK. Pregnancy-associated osteoporosis: a UK case series and literature review. *Osteoporos Int* 2019;30:939-948.
2. Sanz- Salvador L, García- Pérez MÁ, Tarín JJ, Cano A. Bone metabolic changes during pregnancy: a period of vulnerability to osteoporosis and fracture. *Eur J Endocrinol* 2015;172: R53-65.
3. Yun KY, Han SE, Kim SC, Joo JK, Lee KS. Pregnancy-related osteoporosis and spinal fractures. *Obstet Gynecol Sci* 2017;60:133-137.
4. Zhang M, Chen P, Li B, Du J, Pan T, Chen J. Approach to the patient with pregnancy and lactation-associated osteoporosis: A case report and a review of the literature. *Medicine (Baltimore)* 2017;96:e8671.
5. Kovacs CS, Ralston SH. Presentation and management of osteoporosis presenting in association with pregnancy or lactation. *Osteoporos Int* 2015;26:2223-41.

---

## Questions

1. Most PAO fragility fractures occur at the:
- A. Upper extremity
  - B. Hip
  - C. Thoracolumbar spine
  - D. A & B

### Critique

PAO related fragility fractures have an impact on women's health usually 3 months following child-birth. The vast majority of PAO fractures are localized in the thoracolumbar spine, while cases of PAO related hip fractures have also been reported.

The correct answer is C.

2. Which of the following has not been described as a pregnancy related osteoporotic vertebral compression fractures risk factor:
- A. Increased BMI
  - B. Low BMI
  - C. Oligomenorrhea
  - D. Gluten enteropathy

### Critique

Pregnancy related OVCFs occur due to a combination of metabolic and mechanical factors. The mechanical alterations during pregnancy affect the anatomy of the spine, while the metabolic factors, including low BMI, reduced physical activity, poor nutrition, inadequate calcium intake, vitamin D insufficiency, smoking, oligomenorrhea, gluten enteropathy, glucocorticoids intake and LMWH administration increase the risk of an OVCF.

The correct answer is A.

3. When is improvement of BMD in PAO cases anticipated?
- A. 6 months after lactation
  - B. 12-18 months after lactation
  - C. 24 months after lactation
  - D. >24 months after lactation

### Critique

PAO is considered a self-limiting disease and spontaneous improvement of BMD in pre-pregnancy levels is typically expected 12-18 months after lactation.

The correct answer is B.