

Clinical Quiz

Needle tract seeding after core biopsy in a knee tumor; should biopsy tract be excised?

I.D. Papanastassiou¹, M.A. Gerochristou², C.P. Zafeiris³, I. Patoulis¹, D. Ntallas¹, D. Isaakidis¹, G. Papageorgiou¹

¹General Oncological Hospital Kifisias "Agioi Anargyroi", Athens, Greece; ²"Andreas Syngros" Hospital, Athens, Greece;

³General Hospital "KAT", Athens, Greece

Keywords: Core Needle Biopsy, Musculoskeletal Tumors, Biopsy Tract, Excision, Local Relapse

Case

A 62 year old male patient presented to our unit with a painful mass of his left distal femur and knee swelling. Imaging studies showed a large osteolytic tumor with extension in the soft tissues (vastus lateralis). Staging CT (chest and abdomen) and Tc-99m-MDP bone scan were positive for lung mass, adrenal and liver lesions as well as multiple bone lesions suggesting possible metastatic cancer. Core needle biopsy (CNB) was successfully performed under local anesthesia, using a semi-automatic 16G biopsy needle (Geotek Medical Ltd, Turkey). The lesion was accessed from the lateral distal femur through the anticipated surgical incision for tumour management and final treatment of impending femur fracture. According to our haematoma prevention protocol per os anticoagulation and non-steroidal anti-inflammatory drugs (NSAIDs) were not administered for 7 days perioperatively and manual pressure was applied for approximately 10 minutes after the biopsy. Pathology results returned positive for non small cell primary lung adenocarcinoma (negative for EGFR mutation).

Due to unrelated non-medical reasons there was a 6-week delay from CNB to the fixation of the impending femoral fracture. By that time a subcutaneous nodule at the biopsy site was evident, indicating a needle track metastasis (Figure 1). A straight lateral incision was performed that included the

needle track; tumor was curetted and poly-methyl-methacrylate (PMMA) was injected at the tumour site. Osteosynthesis of the distal femur was successfully carried out with an anatomical locking plate (Figure 2). Histopathological examination of the excised tract confirmed the suspected tumor contamination. Immunohistochemical staining was strongly positive for expression of e-cadherin and b-catenin. Indeed, it has been suggested that local invasion and metastatic spread is related to altered expression of the cadherin/ catenin complex. There was no local recurrence (LR) or hardware failure until the patient succumbed to his disease, 6 months later.

Commentary

Needle track seeding has been infrequently described in various types of cancer and sarcomas. More often it is encountered after biopsy of abdominal organs such as liver, pancreas and kidney; thyroid, breast or transthoracic lung CNB may also disseminate cancerous cells in the needle track. In hepatocellular carcinomas it may be as high as 5% as suggested by some series; tumor size, grade, multiple attempts, bigger needles and deep seated tumors are risk factors¹.

However, in musculoskeletal tumors the phenomenon is rare with few case reports published. In a series of 363 tumors (120 bone tumors), no cases of tumor seeding was reported (as defined by the absence of LR)². Other authors also suggest that excision of the needle track is not necessary neither in bone³ or soft tissue tumors⁴ since it does not increase the incidence of LR. This is in contrary to open biopsies where the risk of LR is multiplied (over 5fold in the series of Cannon et al) and it is a common practice to resect the biopsy track, preferably enbloc with the tumor.

Overall, the issue of whether the biopsy tract in CNBs should be resected is controversial; despite lack of evidence based data, other authors advocate CNBs to be made along the an-

The authors have no conflict of interest. All the authors have contributed to the intellectual content of this paper.

Corresponding author: Ioannis Dimitri Papanastassiou, MD, PhD, General Oncological Hospital Kifisias "Agioi Anargyroi", Kalyftaki, Athens, 14564 Greece

E-mail: ioannis.papanastassiou@gmail.com

Edited by: P. Makras

Accepted 11 April 2016



anticipated surgical scar and needle track be excised if possible⁵. A recent systematic review from Oliveira et al in musculoskeletal tumors comes to the same conclusion: without resection of the biopsy tract, the possibility of LR is probably increased and may yield unfavorable prognosis. Interestingly in this review, 2 studies where histological analysis of the needle tract was performed, report unacceptable high rates of tumor con-

tamination (15-22.5%); these data are in agreement with our observation and highlight the fact that probably the overall incidence of tumor seeding is underestimated and overlooked by the musculoskeletal tumor society.

To our knowledge, this is the first case describing tumor seeding in the CNB track of lung cancer metastasis in the appendicular skeleton. A similar case was described in a lung cancer patient undergoing bone marrow aspiration from the iliac crest.

Many useful conclusions may be drawn; the delay in treatment allowed for the recognition of LR from the biopsy tract. If the patient was operated immediately this could have been missed and tumor cells left behind, increasing the likelihood of future recurrence and treatment failure. Although chemotherapy may have eradicated microscopic disease, our report shows that LR due to needle seeding should be taken into account when performing CNBs. This risk may obviate the need for CNB in selected cases where surgery is unavoidable and staging studies strongly favour metastatic disease.

Important points to be made are: 1) CNB should be performed along the standard anticipated surgical incision if possible. We realize though that this is not always possible (nor justified from the literature as discussed above) since it may not give the higher diagnostic yield or make the procedure complex (ie. having to penetrate a great amount of healthy bone). 2) The biopsy site should be marked (ie. with indelible skin mark or methylene blue injection) and reported, so that the surgeon may identify it at the time of operation. 3) A perpendicular direction will also make excision of the tract easier. 4) Although not mandatory, excision of the needle biopsy tract is desirable, especially for radioresistant tumors or where RT will not be routinely administered. 5) If identification of the biopsy tract is not possible or disregarded at the operation, the radiotherapist should be informed to include it in the radiation field.

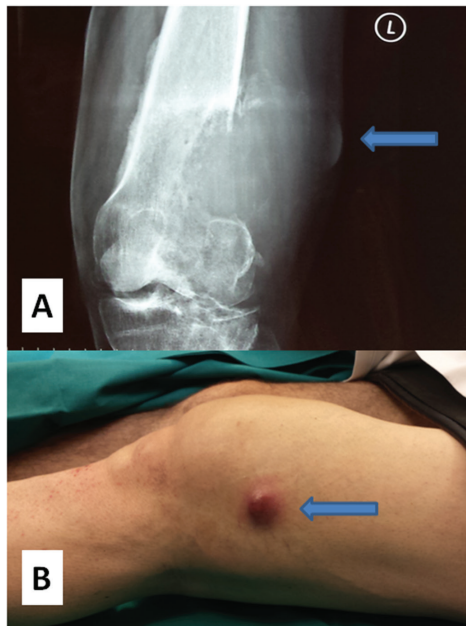


Figure 1. A: anteroposterior x-ray and B: Clinical image, denoting the subcutaneous nodule due to needle track seeding (blue arrow).

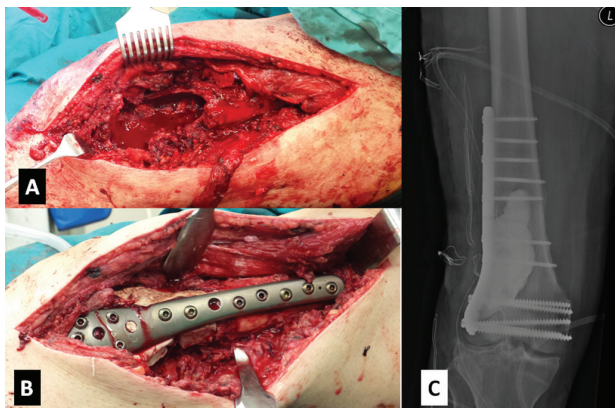


Figure 2. A/B: Intraoperative images showing tumor curettage (A) and fixation with PMMA-locking plate (B). An immediate postoperative anteroposterior x-ray is also depicted (C).

References

1. Tyagi R, Dey P. Needle tract seeding: an avoidable complication. *Diagnostic cytopathology* 2014;42(7):636-640.
2. UyBico SJ, Motamedi K, Omura MC, et al. Relevance of compartmental anatomic guidelines for biopsy of musculoskeletal tumors: retrospective review of 363 biopsies over a 6-year period. *Journal of vascular and interventional radiology: JVIR* 2012;23(4):511-518, 518 e511-512.
3. Saghieh S, Masrouha KZ, Musallam KM, Mahfouz R, Abboud M, Khoury NJ, et al. The risk of local recurrence along the core-needle biopsy tract in patients with bone sarcomas. *The Iowa orthopaedic journal* 2010;30:80-83.
4. Binitie O, Tejiram S, Conway S, Cheong D, Temple HT, Letson GD. Adult soft tissue sarcoma local recurrence after adjuvant treatment without resection of core needle biopsy tract. *Clinical orthopaedics and related research* 2013;471(3):891-898.

5. Liu PT, Valadez SD, Chivers FS, Roberts CC, Beauchamp CP. Anatomically based guidelines for core needle biopsy of bone tumors: implications for limb-sparing surgery.

Radiographics: a review publication of the Radiological Society of North America, Inc 2007;27(1):189-205; discussion 206.

Questions

1. Is needle tract seeding more common in CNBs in musculoskeletal tumors or in solid organ tumors (ie. liver, thorax)?

- A. In musculoskeletal tumors
- B. In solid organs
- C. Equal
- D. Needle tract seeding does not happen in CNBs.

Critique

Needle tract seeding is not uncommon in solid organs (especially in abdominal organs or lung biopsies). In liver percutaneous biopsies, it may be as high as 5%. However, in musculoskeletal tumors where frequently manual pressure can be applied to ensure haemostasis, the phenomenon is rare. The correct answer is B.

2. Is local recurrence (LR) more often in open or closed biopsies (if the biopsy tract is not removed surgically)?

- A. In open biopsies
- B. In closed biopsies
- C. Equal.
- D. LR is not increased either in open or closed biopsies.

Critique

LR is common after open biopsies if the tract is not removed (over 5fold increase in the rate of recurrence). This does not apply for closed biopsies, where the risk is much lower (zero in some series).

The correct answer is A.

3. Should the biopsy tract be excised in CNBs in musculoskeletal tumors?

- A. Yes.
- B. No.
- C. Controversial.
- D. Controversial (although beneficial).

Critique

This is a controversial issue, with some authors claiming that it is not essential, since it does not increase LR plus many times it is difficult to discern the needle tract. Others though argue that the possibility is real and therefore tract excision is desirable if possible; we share the same notion, since it does not add morbidity to the operation, providing that the biopsy is done along the expected surgical pathway. The correct answer is D.