

# Yes, you can see cartilage with X-rays; diffraction enhanced X-ray imaging for soft and hard tissues

C. Muehleman<sup>1</sup>, J. Li<sup>2</sup>, M. Wernick<sup>3</sup>, J. Brankov<sup>3</sup>, K. Kuettner<sup>2</sup>, Z. Zhong<sup>4</sup>

<sup>1</sup>Department of Anatomy and Cell Biology, Rush University Medical Center, Chicago, IL, USA,

<sup>2</sup>Department of Biochemistry, Rush University Medical Center, Chicago, IL, USA, <sup>3</sup>Department of Electrical and Computer Engineering, Illinois Institute of Technology, Chicago, IL, USA, <sup>4</sup>National Synchrotron Light Source, Brookhaven National Laboratory, Upton, New York, USA

**Keywords:** Cartilage, Imaging, DEI, Radiography

## Introduction

Although conventional radiography is simple, inexpensive and well understood<sup>1</sup>, further developments of its applications and capabilities in biologic imaging were previously thought to be at an impasse. Diffraction enhanced imaging (DEI) is an extremely new radiographic field that may have very broad applications due to the greatly increased contrast provided by DE images at lower delivered X-ray doses. To date, nearly all DE images have been acquired at synchrotron sources. However, the technique is not intrinsically tied to the synchrotron, and efforts are currently underway to develop compact DEI technology. DEI utilizes a monochromatic, parallel incident X-ray beam to increase the spatial resolution and increase the contrast by lowering the coherently and incoherently scattered radiation. The further utilization of a crystal analyzer between the object to be imaged and the detector eliminates coherently scattered, incoherently scattered and diffracted intensity from the detected beam that falls outside the angular acceptance of the analyzing crystal (typically on the order of a few microradians). This leaves only the part of the beam that has undergone absorption, extinction, and refraction to reach the detector. In DEI, two images are acquired, one on each side of the analyzer crystal intensity (or rocking) curve, and each contains information about the object's apparent absorption and refraction. Another image is acquired on the peak of rocking curve which contains the object's absorption and extinction information.

DEI has recently allowed us to visualize normal and degenerated articular cartilage in intact joints and other soft tissues surrounding these joints<sup>2-6</sup>. Cartilage provides a smooth,

gliding surface on joints that cushions the underlying bone. However, cartilage is one of the very few tissues in the body that has an exceptionally diminished ability to repair itself after damage, or after the initiation of degenerative changes leading to osteoarthritis. Thus, it is essential to detect the initiation of pathological changes so that early attempts may be made to inhibit disease progression. Imaging of cartilage and other soft tissues through conventional X-ray radiography is virtually impossible since cartilage is almost completely transparent via this technique. Thus, the conventional radiographic evaluation of OA is based on the narrowing of joint space as cartilage is destroyed, and on the presence of bone changes. DEI is uniquely capable of visualizing cartilage with X-rays before this irreparable damage occurs. Hence, we have been able to visualize both the cartilage and bone, simultaneously, in DEI images of synovial joints. Here we show the application of DEI to a set of normal human knee joints.

## Methods

### Specimens

Five human knee joints were obtained, with Institutional IRB approval, from the Gift of Hope Organ and Tissue Donor Network of Illinois. They were imaged in the 10% formalin-preserved state, we have previously shown that fixation has no effect on DEI images<sup>7</sup>.

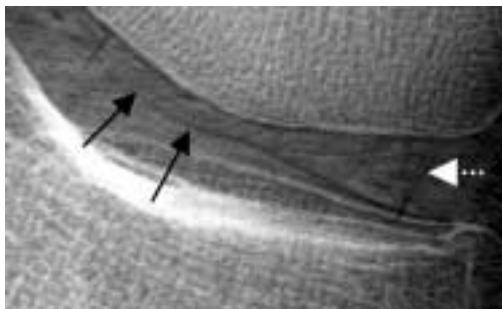
### DEI system and imaging

Radiographic imaging was carried out at the X15A beamline at the National Synchrotron Light Source (NSLS), Brookhaven National Laboratory, Upton, NY. The DEI technique has previously been described<sup>2,3</sup>, but briefly, a collimated fan beam of X-rays is prepared by a silicon [3,3,3] double crystal monochromator. The imaging beam is 130 mm wide and 3 mm high at the location of the object. The X-ray beam transmitted through the object could be either imaged directly, as in "standard radiography", or after diffraction in the vertical plane

The authors have no conflict of interest.

Corresponding author: Carol Muehleman, Ph.D., Department of Anatomy and Cell Biology, ACFAC 507, 600 S. Paulina St. Chicago, IL. 60612, USA  
E-mail: carol\_muehleman@rush.edu.

Accepted 4 August 2004



**Figure 1.** DE image of the medial compartment of a human knee joint showing the femoral cartilage border (black arrows) and the meniscus (white arrow).

by means of the silicon crystal analyzer to acquire the DEI image. The analyzer detects the object's X-ray scattering and refraction at the microradian level, a sensitivity for tissues of similar densities beyond that of conventional radiography.

The greatest absorption information is attained at the peak, or 0 point, of the rocking, or intensity, curve as assessed through the analyzer crystal. To extract refraction information, the analyzer is typically set to the half intensity points on the negative and/or positive slope of the intensity curve. At these points, subtle angle variations are converted into intensity variations, which make refraction effects visible in DEI images. Thus, all DEI images were taken at 40 keV and at  $-0.8$ ,  $0$ , and  $+0.8 \mu\text{rad}$  of the intensity curve<sup>14,15</sup>. The distance between the subject and the detector or image plate was 1 m. Images were acquired with an image plate reader (Fuji Medical Systems, model BAS2500). The resolution of the image obtained is limited by image plate resolution which is approximately 50 microns.

## Results

The articular cartilage and menisci were visible in each of the knee joints, even though these tissues were superimposed by other surrounding soft tissues such as ligaments, tendons, and other connective tissues. A DEI image of the medial compartment of one of the knee joints can be seen in Figure 1. It was found that the best point on the intensity curve for visualizing the edges of the cartilage was at the shoulders of the rocking curve ( $+0.8$  and  $-0.8$  of rocking curve).

## Discussion

Here we have shown that the articular cartilage and menisci of human, normal knee joints can be visualized radiographically utilizing DEI technology. The edges of the cartilage, in particular, can be identified when the analyzer crystal, between the specimen and image plate, is set at the shoulders, or half intensity points, of the rocking curve. It is at these beam intensities that the greatest amount of refraction information from the specimen is procured, thus making

boundaries between tissues of different densities quite apparent. Because of this edge enhancement by DEI, we expect that the identification of surface lesions will be a tenable outcome, thus making early cartilage degeneration recognizable.

We have recently reported on a technique that carries DEI technology one step further, Multiple Image Radiography, or MIR<sup>4</sup>. This technique uses DEI technology, but it allows the extraction of attenuation, refraction, and scatter qualities of an image and their separate display. Thus, our hope is that MIR can be used for the identification of the change in character of a tissue within its MIR image after pathological change. For instance, the scatter properties of articular cartilage that has surface irregularities will be quite different from that of a smooth, regular cartilage surface. Thus, the logical next step in our experimentation will be the application of MIR to joints of known cartilage pathology to determine the level of recognition of cartilage degeneration with MIR.

### Acknowledgements

*We wish to thank the organ donors and the families of the organ donors to the Gift of Hope Organ and Tissue Donor Network. This work was supported by NIH grant R01 AR48292.*

## References

1. Dieppe P, Cushnaghan J, McAlindon T. Epidemiology, clinical course, and outcome of knee osteoarthritis. In: Kuettner KE, Schleyerbach R, Peyron JG, Hascall VC (eds) Articular Cartilage and Osteoarthritis. Raven Press, New York; 1992:617-628.
2. Muehleman C, Chapman LD, Kuettner KE, Mollenhauer J, Rieff J, Zhong Z. Radiography of rabbit articular cartilage with diffraction enhanced imaging. *Anat Rec* 2003; 272A:392-397.
3. Li J, Zhong Z, Lidtke R, Kuettner KE, Peterfy C, Aliyeva E, Muehleman C. Radiography of Soft Tissue of the Foot and Ankle with Diffraction Enhanced Imaging. *J Anat* 2003; 202:463-470.
4. Wernick MN, Wirjadi O, Chapman D, Zhong Z, Galatsanos NP, Yang Y, Brankov JG, Oltulu O, Anastasio MA, Muehleman C. Multiple-image radiography. *Phys Med Biol* 2003; 48:3875-3895.
5. Muehleman C, Sumner R, Zhong Z. Muehleman C, Majumdar S, Arfelli F, Menk RH, Rigon L, Heitner G, Reime B, Metge J, Wagner A, Kuettner KE, Mollenhauer J. X-ray detection of structural orientation in human articular cartilage. *Osteoarthritis Cartilage* 2004; 12:97-105.
6. Muehleman C, Sumner DR, Zhong Z. A new look at bone: refraction effects of diffraction enhanced X-ray imaging. *J Podiat Med* 2004; (in press).
7. Mollenhauer JA, Aurich ME, Zhong A, Muehleman C, Cole AA, Hasna M, Oltulu O, Kuettner KE, Margulis A, Chapman LD. Diffraction enhanced X-ray imaging of articular cartilage. *Osteoarthritis Cartilage* 2002; 10:163-171.